



# PERIO POINTERS

## Acute Necrotizing Ulcerative Gingivitis

As a periodontist, I rarely see ANUG. I want to review my recommendations for treatment:

Hydrogen peroxide rinses 4Xday (1/4 glass peroxide, rest water)

Follow with warm salt water rinses (1 tsp salt per 8 oz glass of water)

Amoxicillin 500 mg tid for 7 days

Brush with an ultra soft brush 3 X day and floss

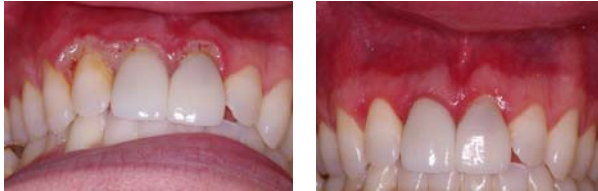
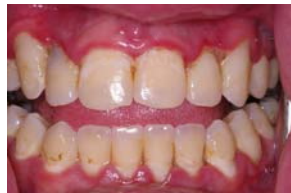
Photo on the right is 2 weeks after the one on the left. The photo below is more common with the punched out papillae.



## Winter 2007 Extra Edition

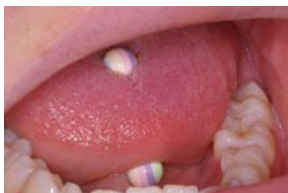

**We make a living by what we get, but we make a life by what we give.**  
Churchill

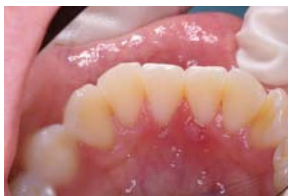## Newsletter Spotlight

This is an extra edition as I came across this material and thought it might be of interest to you. I am sure most of you have seen tooth damage with piercings but you can also have periodontal problems.

## Case Study Trauma from Tongue Bar

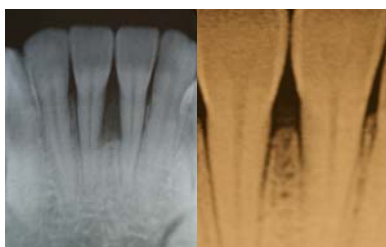


The top photo shows the tongue bar. It does not matter if it is metal or plastic. They both do damage to the teeth and the periodontium.



The lingual photo shows the periodontal abscess on #24 and #25.

The area was flapped, debrided and a freeze-dried demineralized bone graft was done.



The xray on the left was taken 9/2006 preoperatively and the xray on the right was taken on 11/2007.

I refused to treat this patient unless she removed the tongue bar and left it out.