



PERIO POINTERS

Cosmetic Crown Lengthening

Facial appearance is of great concern to the baby boomer generation. They want to look good, feel good, and they have the resources to get what they want. One of the keys is to find out what they want and then let them know what can be done.

If you have a patient who has a **gummy smile, ugly maxillary teeth, malpositioned teeth, worn down teeth, inverse smile line**, they might be a candidate for a smile makeover. Ask the patient if they are happy with their smile. Ask them if there was something they would like to change about their smile. You may be able to point out things that they do not see, like **length, smile line, gingival contour, asymmetry, tooth position, or color**. If they have a real interest, then I would suggest the following:

- Take preoperative photographs including a full face photograph with a smile
- Take preoperative study models
- Do a complete examination including periodontal probings, caries detection and soft tissue examination
- Take full mouth periapical x-rays and perhaps a panoramic radiograph
- Send photograph to SmileVision for a simulation as to what could be done
- An option would be to have a diagnostic wax up done
- Evaluate smile line
- Measure height of teeth
- Evaluate the occlusion
- Mount the models on an articulator
- Perhaps an orthodontic consultation
- Perhaps a periodontal consultation
- Create a stent of where you would like the incisal edge and height of the gingiva

(If there is no real commitment by the patient, you may have planted a seed that will get them thinking about possible changes in the future)

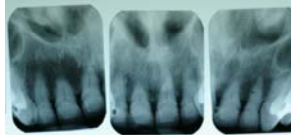
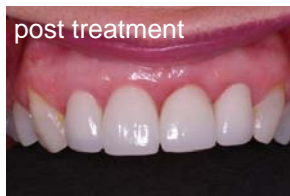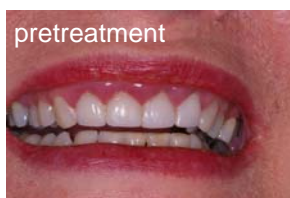September 2007



Success is failure turned inside out.

Newsletter Spotlight

Since I really enjoy doing the cosmetic aspect of dentistry, I plan on doing a series on cosmetic crown lengthening. We will start off with this months issue on why and perhaps how to get the patient to proceed. We will show a series of cases including when we would flap, or do a gingivectomy, take care of asymmetry, do crown shortening, and most importantly discuss some of the situations that could lead to a less than ideal result.



This patient had cosmetic crown lengthening and crowns done 4 years ago. The crowns have 1 mm open margins and the gingivectomy was the wrong choice for crown lengthening.



Flaps and osseous recontouring and new crowns were done on 7,8,9,10.

The full face photo shows a happy patient, and an excellent result by her dentist.

